



# What's New in the Treatment of Focal Chondral Defects of the Knee?

By Christian Lattermann, MD; Richard W. Kang, BS; Brian J. Cole, MD  
*ORTHOPEDICS* 2006; 29:898

October 2006

Chondral and osteochondral restoration treatment techniques are relatively new and rapidly evolving, and represent a tremendous potential to restore functionality in predominantly younger patients.

Articular cartilage injuries in the knee have been recognized as a cause of significant morbidity and disability since the early 19th century.<sup>1</sup> Each year it is estimated that chondral lesions affect up to 900,000 individuals in the United States resulting in over 200,000 surgical procedures, most of which are diagnostic arthroscopies and simple debridements.<sup>2</sup> The use of arthroscopic techniques has enhanced the ability to detect and determine the extent of isolated or combined cartilage injuries following ligament tears or articular fractures. While it is generally accepted that focal chondral lesions often progress towards osteoarthritis, a review of the literature presents compelling evidence that between 11% and 40% of all patients aged <40 years undergoing arthroscopic surgery for other reasons have treatable chondral injuries that will remain unaddressed.<sup>3-5</sup> Chondral and osteochondral restoration treatment techniques are relatively new and rapidly evolving, and represent a tremendous potential to restore functionality in predominantly younger patients. The treatment algorithms for these injuries are complex and often involve multiple procedures such as marrow stimulation, cell transplantation, osteochondral grafting, and bony corrections such as osteotomies.

This article reviews the current articular cartilage restoration techniques and their published results and introduces patient profiling, improved imaging technology, and emerging technologies that may soon become available to the United States market.

## Diagnosis and Classification of Cartilage Injuries

Patient history, physical examination, radiographs and magnetic resonance imaging (MRI) are usually sufficient to diagnose a cartilage injury. It is important to differentiate patients who have isolated or multiple focal chondral lesions from patients with diffuse osteoarthritic changes. Patients with focal chondral defects usually have normal range of motion (ROM) and possibly focal tenderness over palpable areas along the lateral or medial femoral condyle during examination. Activity-related effusions also may be present. Patients with focal chondral defects usually are young, active and can perform activities of daily living (ADL), although they often will report activity-specific pain (ie, symptoms during deep squatting, cutting). However, accompanying injuries and bony malalignment are common in patients with focal chondral defects and must be carefully assessed and documented since these affect the decision-making regarding treatment options. Patients with more diffuse cartilage damage usually show a subtle decrease in ROM (flexion earlier than extension). They often present with chronic effusions, and more diffuse rather than focal pain during their ADL. These patients continue to represent a treatment challenge as they often are less responsive to cartilage repair techniques.

Classification of articular cartilage injuries has been difficult due to the lack of objective measurements. The Outerbridge classification is the most widely used classification system to describe the size of a cartilage lesion.<sup>6</sup> It provides a distinction between a partial (Grades 1 and 2) versus nearly full or full-thickness cartilage defect (Grades 3 and 4); between a small (Grade 2) and larger (Grade 3) lesion; and describes a complete loss of cartilage (Grade 4). The Outerbridge classification, however, has specific limitations. For example, a 433 cm partial thickness defect with a potentially bad prognosis due to its size is classified as a Grade 1 defect, whereas a direct cut or narrow fissure is classified as a Grade 4 defect. These limitations have prompted the International Cartilage Repair Society (ICRS) to introduce a modified classification system that focuses on the depth of the cartilage injury (Table). Combined with visual measurement, the modified ICRS classification has the potential to better describe the defect macroscopically and correlates better with clinical outcome.<sup>7</sup>

Table	
ICRS grading Score <sup>7</sup>	
Grade	Properties
1	Superficial lesions, fissures, cracks, and indentations
2	Fraying, lesions extending down to <50% of cartilage depth
3	Partial loss of cartilage thickness, cartilage defects extending down >50% of cartilage depth as well as down to calcified layer
4	Complete loss of cartilage thickness, bone only

Plain radiographs effectively aid the diagnosis and evaluation of osteoarthritis or chondropenia. The standard cartilage radiograph series for the knee should include bilateral standing anteroposterior, 45° flexion weight bearing posteroanterior, and nonweight bearing lateral and patella sunrise views. Subtle joint space narrowing, subchondral sclerosis, osteochondral defects, osteophytes, and cysts can easily be identified on these views.

Although MRI is best used in the assessment of concomitant injuries, special articular cartilage sequences can aid the diagnosis and evaluation of cartilage injury. It should be appreciated, however, that while these sequences are helpful to assess large focal chondral defects, they generally underestimate the extent of the actual chondral injury. More recently, novel MRI techniques such as the delayed Gadolinium-Enhanced MRI of Cartilage (dGEMRIC) and T2 relaxation time mapping, hold great promise in the evaluation of articular cartilage. dGEMRIC is a noninvasive imaging technique that visualizes the glycosaminoglycan (GAG) content in cartilage<sup>8</sup> and effectively aids in the evaluation of early knee osteoarthritis<sup>9</sup> and cartilage health, subsequent to ligament rupture.<sup>10</sup> dGEMRIC also provides measurement of compressive stiffness following cartilage repair procedures.<sup>11,12</sup> Another technique, T2 relaxation time mapping, can be used to measure the collagen content of cartilage. This MRI parameter represents the internuclear reaction secondary to the transverse relaxation of excited hydrogen dipoles.<sup>13</sup> T2 has demonstrated potential usefulness in the determination of histological degeneration of cartilage, and provides the ability to map anatomical zones of cartilage and the longitudinal evaluation of cartilage from the time of injury to determine optimal surgical intervention, if needed.<sup>14</sup> Importantly, dGEMRIC and T2 mapping provide noninvasive means to detect early matrix changes before discernable morphologic alteration. Thus, they have significant potential to help ascertain the extent of cartilage damage, and will provide objective information towards the determination of an optimal window of treatment using effective cartilage restoration procedures.

## Current Treatment Techniques

Various techniques have been described and are in use that attempt to promote the regeneration of articular cartilage. While none of the currently available techniques result in full regeneration of articular cartilage, it is important to understand the technical differences and nuances between them to maximize their clinical efficacy. Additionally, a broader understanding of cartilage restoration techniques and their associated outcomes will assist the reader in appreciating the direction of emerging technologies in cartilage repair.

### Microfracture

Microfracture is a technique that uses controlled subchondral perforations that allow marrow elements (mesenchymal cells, growth factors) to accumulate in the chondral defect. The perforations initiate the formation of a “superclot” that forms at the time of surgery, which then remodels over the course of 6-12 months into a fibrocartilaginous repair tissue. Although the repair tissue consists predominantly of collagen type I and resembles fibrocartilage more than hyaline cartilage (eg, the repair tissue does not resist shear and compression loads as predictably as normal hyaline cartilage), overall, microfracture is a low-morbidity procedure. This treatment technique is widely used and well documented. If performed correctly it has great potential for symptomatic improvement: recent examples of favorable outcomes include a report by Steadman et al<sup>15</sup> summarizing 11 years of significant subjective improvement in treated patients, and a report by Gobbi et al<sup>16</sup> documenting subjective and objective improvements in 109 patients at an average of 72 months follow-up.<sup>16</sup> Additional reports include a case series by Mithoefer et al<sup>17</sup> consisting of 20 patients with focal chondral defects of varying sizes; 61% of these patients were participating in professional or highly competitive cutting/pivoting sports at the time of injury. Following microfracture treatment, up to 47% of patients continued participation in sports, but only 20% at the pre-injury level.

Notably, this study concluded that younger patients (aged <40 years) with lesions <200 mm<sup>2</sup> and preoperative symptoms of <12 months return to sports activities in significantly higher numbers than other patients.<sup>17</sup> In an earlier study the same authors showed that high body mass index (>30) and duration of symptoms are negative predictive factors for a good outcome.<sup>18</sup> In a similar study, Kreuz et al<sup>19</sup> compared 18- versus 36-month follow-up outcomes in 85 patients following microfracture treatment of various size defects using the Cincinnati and ICERS scoring systems. This study demonstrated that at 18 months post-procedure, patients with condylar defects maintain their scores whereas patients with other defect localizations significantly deteriorate. This study also corroborates the findings of Mithoefer et al<sup>17</sup> that patients aged >40 years have significantly lower outcome scores at all time points.

Microfracture therapy is often chosen as the benchmark for which to compare other cartilage repair procedures. Knutsen et al<sup>20</sup> found no significant differences between microfracture treatment and autologous chondrocyte implantation at 2-year follow-up in a prospective randomized clinical trial using the Tegner as well as the International Knee Documentation Committee (IKDC) scoring systems. Wasiak et al mentioned in their meta-analysis a randomized clinical trial performed by Basad et al that also reported no significant differences in the Tegner, Lysholm, or IKDC scores between microfracture and the matrix-guided autologous chondrocyte implantation at 24-month follow-up.<sup>21</sup>

Despite its relative success, a contraindication to microfracture is a patient's unwillingness or inability to undergo the necessary postoperative rehabilitation that typically requires 4-6 weeks of protected weight bearing and continuous passive motion.

### **Autologous Chondrocyte Implantation**

Autologous chondrocyte implantation is a cartilage restorative procedure in which a small amount (200-300 mg) of healthy, autologous cartilage is harvested from the patient, typically during an initial arthroscopic evaluation of the chondral lesion. The tissue is then enzymatically treated in the laboratory to release chondrocytes, followed by isolation, purification, and expansion before reimplantation into the lesion. The goal of autologous chondrocyte implantation is to restore hyaline cartilage (>90% collagen type II). Histological studies and direct enzymatic quantitative measurements have demonstrated that autologous chondrocyte implantation produces a "hyaline-like cartilage" with a collagen type II content between 35% and 55%. This repair tissue may have greater, more authentic biomechanical properties than the fibrocartilage regenerated in similar lesions repaired by chondroplasty or microfracture.

Since the initial report by Brittberg et al<sup>22</sup> describing autologous chondrocyte implantation, this technique has been adopted worldwide to treat cartilage defects in humans. Although Peterson et al<sup>23</sup> initially reported an overall success rate of 89% for isolated femoral lesions 2-9 years following autologous chondrocyte implantation, a lower success rate (62%) was seen in high pressure areas such as the patella. Anecdotal evidence exists for improved outcomes for patellofemoral joint treatment if an anteromedialization osteotomy was added.<sup>24</sup> Bentley et al<sup>25</sup> demonstrated in a randomized clinical trial that autologous chondrocyte implantation compares favorably with autologous chondral plugs (mosaicplasty) at 1-year follow-up. Although they reported 88% good and excellent results (Cincinnati score) for autologous chondrocyte implantation treatment of defects on the medial femoral condyle, these encouraging results could not be duplicated with patellar, trochlear or lateral condylar defects.<sup>25</sup>

The ideal indication for autologous chondrocyte implantation is the symptomatic, unipolar, well-contained defect between 2 cm<sup>2</sup> and 10 cm<sup>2</sup> that does not violate the subchondral bone. Autologous chondrocyte implantation often is performed in patients who failed traditional first-line treatments such as debridement, microfracture, or osteochondral autograft techniques. Contraindications for this procedure are bipolar lesions and lesions with significant bone loss. As for any of the cartilage restoration procedures, it is imperative that concomitant malalignment, ligament instability, and meniscus deficiency are corrected prior to or at the time of index surgery. The most common complication of autologous chondrocyte implantation is hypertrophy of the regenerating tissue (up to 20%), possibly related to the periosteum patch used in this procedure.<sup>25</sup> This complication can be successfully treated with an arthroscopic debridement. Rehabilitation following autologous chondrocyte implantation is similar to that which is required following microfracture.

### **Osteochondral Grafts**

Osteochondral grafting, the direct transplantation of an osteochondral autograft or allograft, is the only technique available that restores hyaline cartilage. Autograft plugs typically are used to treat relatively small defects (eg, ≤20 mm<sup>2</sup>), due to donor site size limitations. Osteochondral allografts can be harvested up to 35 mm in diameter; greater allografts can be obtained if a hand-fashioned "shell" grafting technique is used. Any allograft technique typically involves preparation of the recipient site as well as the donor plug using a coring reamer or drill. While osteochondral autograft procedures are limited by potential donor site morbidity, osteochondral allografts pose the

risk of disease transmission and a possible graft-versus-host immune response against the donor tissue. Therefore, a fresh osteochondral allograft should be implanted only after its sterility and lack of transmissible diseases has been verified. Maximal chondrocyte viability is maintained in grafts implanted no greater than 28 days post-harvest.<sup>26</sup>

Clinical outcome of osteochondral autografts has been documented in various studies. Hangody et al<sup>27</sup> reported good or excellent results in 79% of patellofemoral lesions, 87% of tibial lesions, and 92% of isolated femoral lesions treated with osteochondral autograft plugs (mosaicplasty). Emerging reports of osteochondral autografts use in other joints have been promising, and include the treatment of the talus,<sup>28</sup> femoral head,<sup>27</sup> and elbow.<sup>29</sup>

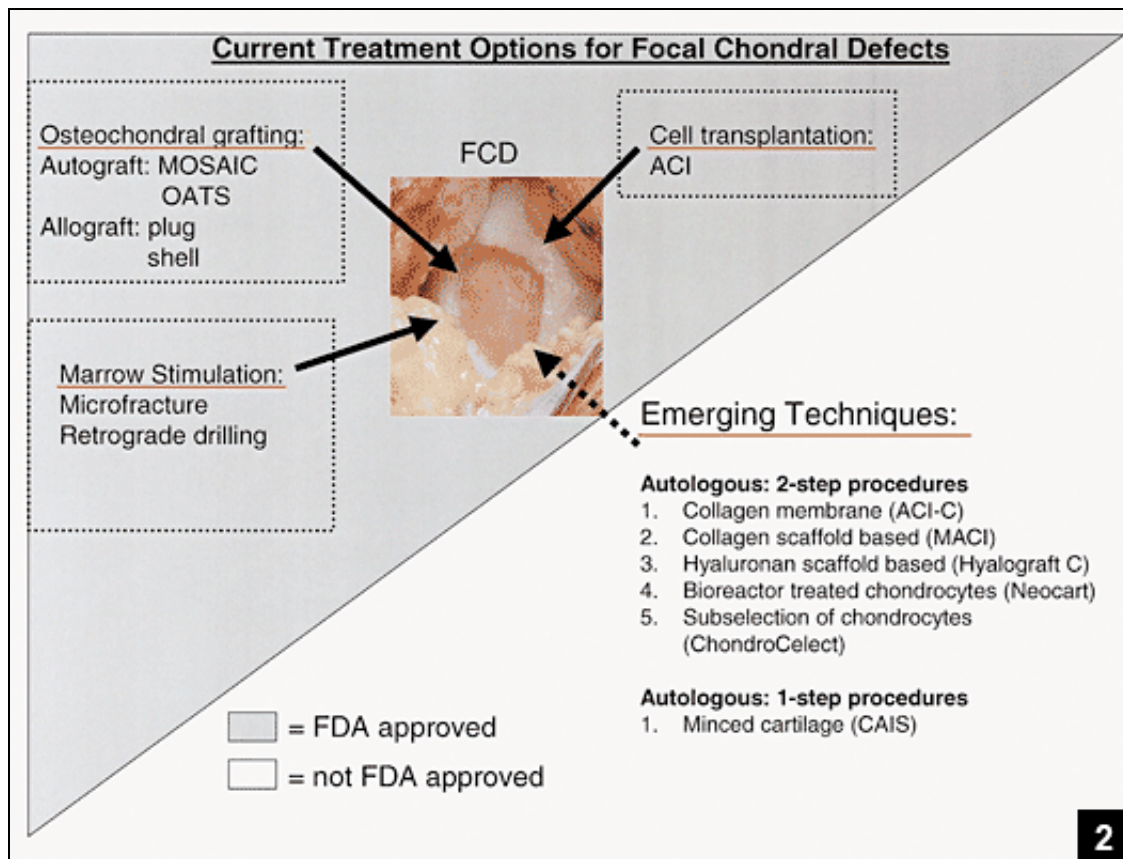
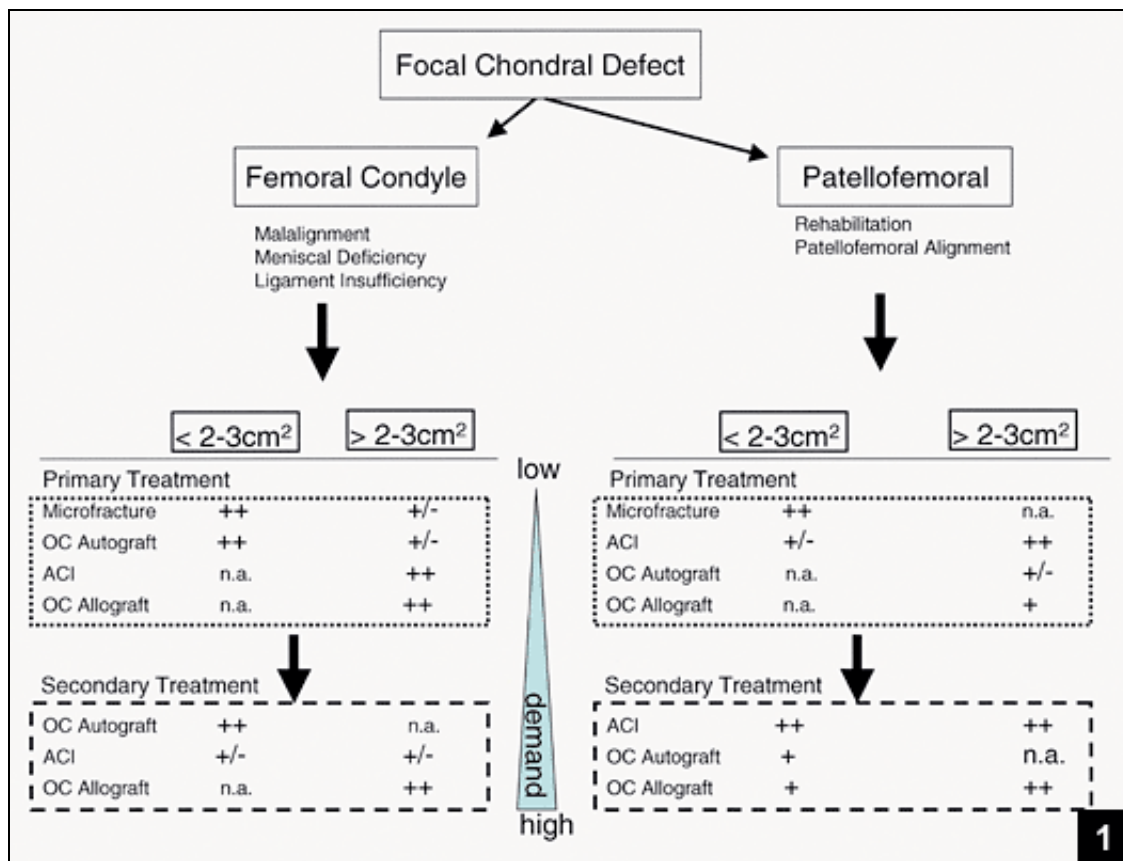
Osteochondral allografting generally has been best for younger patients with isolated traumatic lesions or osteochondritis dissecans. In 1985, McDermott et al<sup>30</sup> reported outcomes of their first 100 osteochondral allograft procedures, in which only 56% of patients demonstrated a good or excellent result at a mean of 3.8 years follow-up. Results have since improved, benefiting from more careful patient selection and advances in allograft processing procedures, surgical technique, and postoperative rehabilitation. Shasha et al<sup>31</sup> reported a 10-year graft survival rate of 71% and a 20-year survival rate of 66%. The senior author's (B.J.C.) patients have reported an overall 84% satisfaction rating, with significant improvements in the IKDC and Knee injury and Osteoarthritis Outcome Score (KOOS) at 2-year follow-up. Eighty-eight percent of the osteochondral allografts were radiographically incorporated at clinical follow-up.

## **Where Are We Today?**

Cartilage repair continues to be an emerging field with tremendous treatment potential for predominantly young and active patients. While some of the more advanced, but currently considered experimental, techniques may revolutionize the field, it is important to optimize current treatment options for the benefit of patients. For this reason it is important to clearly identify the appropriate indications and contraindications, and to optimize patient selection and manage all comorbidities. This "patient profiling" assures the best possible outcome for each patient and prevents unrealistic expectations.

Krishnan et al<sup>32</sup> investigated the prognostic indicators for autologous chondrocyte implantation and reported that younger patients with high preoperative scores, a <2-year history of symptoms, a single defect, trochlear or femoral condylar defects, and <2 previous surgical procedures are positive outcome predictors. Revision autologous chondrocyte implantation in previously failed autologous chondrocyte implantation and mosaicplasties showed significantly inferior results to primary procedures.

Over the past decade, clinical and basic science research has provided us with the foundation for successful treatment of focal cartilage defects. While techniques such as microfracture, autologous chondrocyte implantation, and osteochondral grafts can restore function to most patients, pitfalls exist with each of these techniques. Microfracture and autologous chondrocyte implantation do not restore hyaline cartilage and therefore may have limited durability. Osteochondral grafts fail to incorporate at the cartilage interface and have shown a propensity to degenerate in preclinical and clinical follow-up, and thus also may fail at mid-term evaluation. True long-term studies assessing any of these techniques for the treatment of focal chondral defects have not been published. Good to excellent mid-term results are reported in the majority of our patients; however, patients have failed the initial procedure. It is therefore crucial to establish a treatment algorithm that considers the potential for failure and yet does not preclude secondary treatment options. The authors have developed a comprehensive treatment algorithm that is delineated in Figure 1. This algorithm assures a treatment protocol that is based on clinical symptoms and enables us to offer appropriate surgical intervention without burning bridges for further treatment options.



**Figure 1:** Treatment algorithm for the treatment of focal chondral defects. This treatment algorithm allows for a careful approach towards treating focal chondral defects avoiding to burn bridges for possible further treatment in the event of failure of the primary treatment option. **Figure 2:** Current treatment options for focal chondral defects. The grey triangle depicts the currently FDA approved treatment options for focal chondral defects. The white area depicts the emerging new technologies. Many of these new technologies are currently approved for clinical use in Europe (ACI-C, MACI, Hyalograft C, ChondroCelect). Some are currently undergoing phase-2 clinical trials in the United States (Neocart, CAIS).

## Emerging Ideas and Techniques

The currently established, Food and Drug Administration-approved techniques provide the foundation and the benchmark for novel techniques (Figure 2). Emerging techniques focus on the restoration of articular cartilage based on the delivery of autologous or allogeneic chondrocytes or stem cells to the focal chondral defect. Autologous chondrocyte implantation opened the door to this technology by proving clinical success and showing the limitations and complications of this procedure. Novel techniques therefore try to circumvent the tedious process of having to manually sew a chamber with locally harvested periosteum. The easiest way to avoid the periosteum harvest is to use a collagen membrane, as shown by Krishnan et al<sup>33</sup> with their autologous chondrocyte implantation-collagen membrane technique: success rates were comparable to that of classic autologous chondrocyte implantation with a lower incidence of chondral hypertrophy. This technique may therefore eliminate one problem facing surgeons in up to 20% of their patients when using traditional autologous chondrocyte implantation technology. Other investigators have seeded chondrocytes directly onto a membrane that acts as a scaffold for the chondrocytes (matrix-induced autologous chondrocyte implantation, Hyalograft C). These scaffold membranes are naturally “sticky” and can be positioned into the defect arthroscopically without additional fixation, and theoretically possess the advantage that chondrocytes can expand in three-dimensional scaffold. This scaffold may allow the chondrocytes to lay down competent matrix prior to implantation, “kick-starting” the process of hyaline or hyaline-like cartilage formation. To date, some of these techniques have demonstrated comparable results to autologous chondrocyte implantation,<sup>34-37</sup> although they are not currently FDA approved. Other groups have recently cultured a scaffold seeded with autologous chondrocytes inside a bioreactor that continuously applies hydrostatic pressure to the scaffold (Neocart; Histogenics, Northampton, Mass), and is currently under investigation in a clinical trial.

A different angle has been investigated by a group in Norway. They noted that subgroups of harvested autologous chondrocytes have a higher potential to proliferate than others, and have developed a mechanism to selectively culture the more potent chondrocytes for re-implantation (ChondroCelect; Tigenix Inc, Leuven, Belgium).<sup>38</sup>

The previously mentioned techniques all depend on the harvest of autologous chondrocytes and subsequent re-implantation, requiring two surgical procedures. A different approach has been described by Lu et al.<sup>39</sup> They used minced donor cartilage placed on a bioabsorbable scaffold. This construct is then stapled into the focal chondral defect. The advantage of this cartilage autograft implantation system (CAIS; Depuy-Mitek, Norwood, Mass) is that it uses autologous cells and only involves a single surgical procedure.

Further on the horizon are tissue engineering concepts that involve genetic manipulation of donor or recipient cells using gene therapy or growth factor therapies. Different scaffolds are being investigated for their suitability to restore articular cartilage. Over the next few years we will see an advent of new tissue-engineered technologies that may provide the opportunity to fully restore articular cartilage in focal chondral defects and will bring us closer to treating osteoarthritis with biologic means.

## References

1. Hunter W. On the structure and diseases of articulating cartilage. *Philos Trans R Soc Lond B Biol Sci.* 1743; 9:267.
2. Curl WW, Krome J, Gordon ES, Rushing J, Smith BP, Poehling GG. Cartilage injuries: a review of 31,516 knee arthroscopies. *Arthroscopy.* 1997; 13:456-460.
3. Alford JW, Cole BJ. Cartilage restoration, part 1: basic science, historical perspective, patient evaluation, and treatment options. *Am J Sports Med.* 2005; 33:295-306.
4. Aroen A, Loken S, Heir S, et al. Articular cartilage lesions in 993 consecutive knee arthroscopies. *Am J Sports Med.* 2004; 32:211-215.
5. Hjelle K, Solheim E, Strand T, Muri R, Brittberg M. Articular cartilage defects in 1,000 knee arthroscopies. *Arthroscopy.* 2002; 18:730-734.
6. Outerbridge RE. The etiology of chondromalacia patellae. *J Bone Joint Surg Br.* 1961; 43:752-757.
7. Kleemann RU, Krockner D, Cedraro A, Tuischer J, Duda GN. Altered cartilage mechanics and histology in knee osteoarthritis: relation to clinical assessment (ICRS Grade). *Osteoarthritis Cartilage.* 2005; 13:958-963.
8. Trattng S, Millington SA, Szomolanyi P, Marlovits S. MR imaging of osteochondral grafts and autologous chondrocyte implantation. *Eur Radiol.* 2006; 27:[Epub ahead of print].
9. Tiderius CJ, Tjornstrand J, Akesson P, Sodersten K, Dahlberg L, Leander P. Delayed gadolinium-enhanced MRI of cartilage (dGEMRIC): intra- and interobserver variability in standardized drawing of regions of interest. *Acta Radiol.* 2004; 45:628-634.
10. Young AA, Stanwell P, Williams A, et al. Glycosaminoglycan content of knee cartilage following posterior cruciate ligament rupture demonstrated by delayed gadolinium-enhanced magnetic resonance imaging of cartilage (dGEMRIC). A case report. *J Bone Joint Surg Am.* 2005; 87:2763-2767.

11. Kurkijarvi JE, Nissi MJ, Kiviranta I, Jurvelin JS, Nieminen MT. Delayed gadolinium-enhanced MRI of cartilage (dGEMRIC) and T2 characteristics of human knee articular cartilage: topographical variation and relationships to mechanical properties. *Magn Reson Med*. 2004; 52:41-46.
12. Gillis A, Bashir A, McKeon B, Scheller A, Gray ML, Burstein D. Magnetic resonance imaging of relative glycosaminoglycan distribution in patients with autologous chondrocyte transplants. *Invest Radiol*. 2001; 36:743-748.
13. Maier CF, Tan SG, Hariharan H, Potter HG. T2 quantitation of articular cartilage at 1.5 T. *J Magn Reson Imaging*. 2003; 17:358-364.
14. Potter HG, Foo LF. Magnetic resonance imaging of articular cartilage: trauma, degeneration, and repair. *Am J Sports Med*. 2006; 34:661-677.
15. Steadman JR, Briggs KK, Rodrigo JJ, Kocher MS, Gill TJ, Rodkey WG. Outcomes of microfracture for traumatic chondral defects of the knee: 11-year follow-up. *Arthroscopy*. 2003; 19:477-484
16. Gobbi A, Nunag P, Malinowski K. Treatment of full thickness chondral lesions of the knee with microfracture in a group of athletes. *Knee Surg Sports Traumatol Arthrosc*. 2005; 13:213-221
17. Mithoefer K, Williams RJ III, Warren RF, et al. The microfracture technique for the treatment of articular cartilage lesions in the knee. A prospective cohort study. *J Bone Joint Surg Am*. 2005; 87:1911-1920.
18. Mithoefer K, Williams RJ III, Warren RF, Wickiewicz TL, Marx RG. High-impact athletics after knee articular cartilage repair: a prospective evaluation of the microfracture technique. *Am J Sports Med*. 2006; 34:1413-1418.
19. Kreuz PC, Steinwachs MR, Erggelet C, et al. Results after microfracture of full-thickness chondral defects in different compartments in the knee. *Osteoarthritis Cartilage*. 2006; [Epub ahead of print].
20. Knutsen G, Engebretsen L, Ludvigsen TC, et al. Autologous chondrocyte implantation compared with microfracture in the knee. A randomized trial. *J Bone Joint Surg Am*. 2004; 86:455-464.
21. Wasiak J, Clar C, Villanueva E. Autologous cartilage implantation for full thickness articular cartilage defects of the knee. *Cochrane Database Syst Rev*. 2006; 3:CD003323.
22. Brittberg M, Lindahl A, Nilsson A, Ohlsson C, Isaksson O, Peterson L. Treatment of deep cartilage defects in the knee with autologous chondrocyte transplantation. *N Engl J Med*. 1994; 331:889-895.
23. Peterson L, Minas T, Brittberg M, Nilsson A, Sjogren-Jansson E, Lindahl A. Two- to 9-year outcome after autologous chondrocyte transplantation of the knee. *Clin Orthop Relat Res*. 2000. 374:212-234
24. Beck PR, Thomas AL, Farr J, Lewis PB, Cole BJ. Trochlear contact pressures after anteromedialization of the tibial tubercle. *Am J Sports Med*. 2005; 33:1710-1715.
25. Bentley G, Biant LC, Carrington RW, et al. A prospective, randomised comparison of autologous chondrocyte implantation versus mosaicplasty for osteochondral defects in the knee. *J Bone Joint Surg Br*. 2003; 85:223-230.
26. Williams JM, Viridi AS, Pylawka TK, Edwards RB III, Markel MB, Cole BJ. Prolonged-fresh preservation of intact whole canine femoral condyles for the potential use as osteochondral allografts. *J Orthop Res*. 2005; 23:831-837.
27. Hangody L, Fules P. Autologous osteochondral mosaicplasty for the treatment of full-thickness defects of weight-bearing joints: ten years of experimental and clinical experience. *J Bone Joint Surg Am*. 2003; 85(Suppl 2):25-32.
28. Hangody L, Kish G, Modis L, et al. Mosaicplasty for the treatment of osteochondritis dissecans of the talus: two to seven year results in 36 patients. *Foot Ankle Int*. 2001; 22:552-558.
29. Bradley JP, Petrie RS. Osteochondritis dissecans of the humeral capitulum. Diagnosis and treatment. *Clin Sports Med*. 2001; 20:565-590
30. McDermott AG, Langer F, Pritzker KP, Gross AE. Fresh small-fragment osteochondral allografts. Long-term follow-up study on first 100 cases. *Clin Orthop Relat Res*. 1985; 197:96-102.
31. Shasha N, Aubin PP, Cheah HK, Davis AM, Agnidis Z, Gross AE. Long-term clinical experience with fresh osteochondral allografts for articular knee defects in high demand patients. *Cell Tissue Bank*. 2002; 3:175-182.
32. Krishnan SP, Skinner JA, Bartlett W, et al. Who is the ideal candidate for autologous chondrocyte implantation? *J Bone Joint Surg Br*. 2006; 88:61-64.
33. Krishnan SP, Skinner JA, Carrington RW, Flanagan AM, Briggs TW, Bentley G. Collagen-covered autologous chondrocyte implantation for osteochondritis dissecans of the knee: two- to seven-year results. *J Bone Joint Surg Br*. 2006; 88:203-205.
34. Behrens P, Bitter T, Kurz B, Russlies M. Matrix-associated autologous chondrocyte transplantation/implantation (MACT/MACI)—5-year follow-up. *Knee*. 2006; 13:194-202.
35. Bartlett W, Skinner JA, Gooding CR, et al. Autologous chondrocyte implantation versus matrix-induced autologous chondrocyte implantation for osteochondral defects of the knee: a prospective, randomized study. *J Bone Joint Surg Br*. 2005; 87:640-645.
36. Gobbi A, Kon E, Berruto M, Francisco R, Filardo G, Marcacci M. Patellofemoral full-thickness chondral defects treated with Hyalograft-C: a clinical, arthroscopic, and histologic review. *Am J Sports Med*. 2006; [Epub ahead of print].
37. Marcacci M, Berruto M, Brocchetta D, et al. Articular cartilage engineering with Hyalograft C: 3-year clinical results. *Clin Orthop Relat Res*. 2005; 435:96-105.
38. De Bari C, Dell'Accio F, Tylzanowski P, Luyten FP. Multipotent mesenchymal stem cells from adult human

synovial membrane. *Arthritis Rheum.* 2001; 44:1928-1942.

39. Lu Y, Dhanaraj S, Wang Z, et al. Minced cartilage without cell culture serves as an effective intraoperative cell source for cartilage repair. *J Orthop Res.* 2006; 24:1261-1270.

## Authors

Dr Lattermann is from University of Kentucky Medical Center, Orthopedic Sports Medicine, Lexington, Ky; Mr Kang is from Orthopedic Sports Medicine and Dr Cole is from Cartilage Restoration Center, Rush Presbyterian University, Chicago, Ill.

Reprint requests: Christian Lattermann, MD, Kentucky Clinic, 740 S Limestone, Ste K401, Lexington, KY 40536-0284.

**Visit us regularly for daily orthopedic news.**

**[About SLACK Inc.](#) | [Contact Us](#) | [Careers](#) | [FAQ](#)**

Copyright © 2010 SLACK Incorporated. All rights reserved.

[GET](#) [CLICKY](#)